




Product Catalog

Get to **know** us!



+55 11 4961.0900

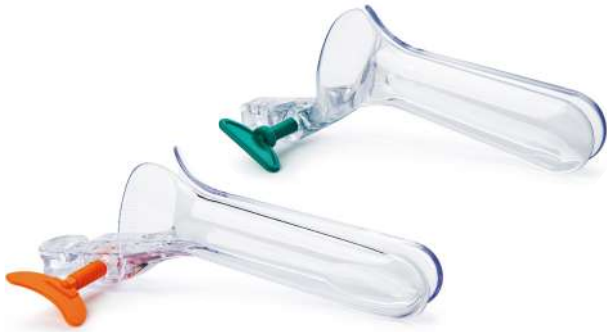vendas@kolplast.com.br

www.kolplast.com.br

ABOUT US

Initially Kolplast, today, Grupo Kolplast, was founded in 1988 in the city of São Paulo, Brazil. More than simple industry of medical and hospital supplies was born. Since its foundation, the Grupo Kolplast was dedicated to offering materialized solutions in the form of products. With this proposal and an attentive and permanently focused eye on the needs of its customers, the Group has traveled a victorious trajectory, carrying alongside references of innovation, practicality, superior quality products and excellent services.





Vaginal Speculum Collins Type

Sterile / Non Sterile / Lubricated

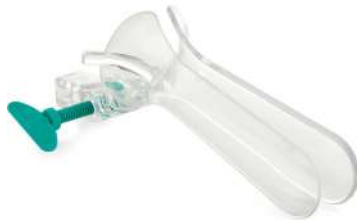Sizes:



Vaginal Speculum with Smoke Evacuator tube

Sterile

Sizes:



Vaginal Speculum for Lightning System - Kolplux

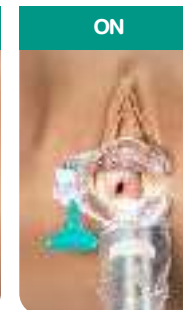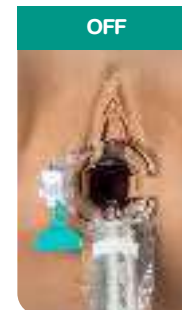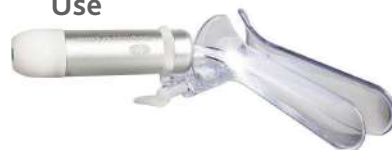Sterile / Not Sterile



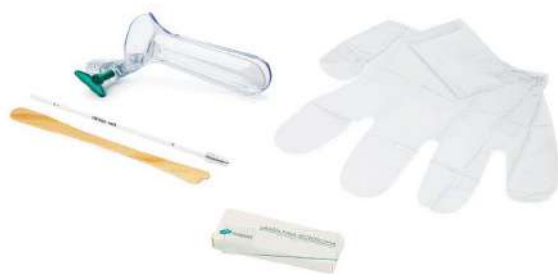LED Light Source for Vaginal Speculum - Kolplux



Use



VAGINAL SPECULUM



Pap Smear

Sterile / Non Sterile

Standard models

Model	Vaginal Speculum	Cervical Brush	Ayre Spatula	Glass Slide	Pair of EVA Gloves
Basic Pap Smear Set I		X	X		
Pap Smear Set I	X	X	X		
Pap Smear Set II	X	X	X	X	
Pap Smear Full Set	X	X	X	X	

*Customizable as per your need



Cervical Brush

Sterile / Non Sterile

Versions: Conventional, Protected Tip and Cone Tip.



Kolpofix - Cytology Fixative Aerosol

 **FDA** CERTIFICATION



Regular Swab

Indicated for Oral, Anal or Vaginal Collections.

Sterile



Swab Nasal

Thin and Flexible Rod, indicated for collections at the nasopharynx region.

Sterile



Collection Kit

Sterile



Saliva Collection Kit


Sterile




KolplaGene

Sterile

Ideal for collecting and transporting biological material for genetic testing.

 Preserves DNA and RNA samples

 Sample stability, for up to 30 days, at room temperature.

Opsis

-10% buffered formalin solution, for cell and tissue preservation, in the biopsy process.



20L



20ml

COLLECTION KIT FOR
BIOLOGICAL MATERIAL

OTHER PRODUCTS



Dessing Kit

Sterile



Umbilical Cord Clamp

Sterile



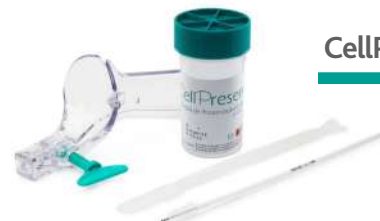Closed Anoscope



Fenestrated Anoscope



TPK Fênix Microscope Slide Processor



CellPreserv Collection Kit



Gyn Filter



Non-Gyn Filter



CellPreserv Solution

Vial 18 ml

CellPreserv
kolplast

LIQUID BASE CITOTOLOGY

Validation of a New Low-Cost, Methanol-Based Fixative for Cervical Cytology and Human Papillomavirus Detection

Katia Ramos Moreira Leite^{a,b} Thais Silva^a Bruna Naum^a Flavio Canavez^a
Juliana Canavez^a Ruan Pimenta^{a,b} Sabrina Reis^b Luiz Heraldo Camara-Lopes^a

^aLaboratório Genoa/LPCM, São Paulo, Brazil; ^bFaculdade de Medicina da Universidade de São Paulo LIM 55, São Paulo, Brazil

Keywords

Liquid-based cytology · ThinPrep · CellPreserv · Human papillomavirus · Cervical intraepithelial neoplasia

Abstract

Objective: To test the performance of a new fixative for pap smear collection for liquid-based cervical cytology, CellPreserv[®] and compare it with the commercially available, PreservCyt[®] used in the diagnosis and detection of human papillomavirus (HPV). **Methods:** Seven hundred twenty five women participated in this study after signing an informed consent. The specimens were collected using a traditional device, agitated in PBS, and equally divided in both fixatives. The slides were prepared routinely, stained by Papanicolaou, examined blindly by 2 cytologists, and reviewed by one cytopathologist. To search for HPV, 1,000 µL from each fixative was taken and processed by polymerase chain reaction. **Results:** Considering the adequacy of samples, both fixatives had similar results – 0.33 and 0.32% of the cases unsatisfactory for PreservCyt[®] and CellPreserv[®], respectively. Considering the 701 satisfactory cases and comparing the new fixative to the traditional fixative, there was 99.3% concordance between both. The results regarding the HPV detection was

100% concordant between the 2 fixatives. **Conclusion:** The new methanol-based fixative, CellPreserv[®], is cheaper and equally efficient for treating cervical cancer screening and for HPV detection, and can be safely used by the health system prevailing in low-income countries.

© 2018 S. Karger AG, Basel

Introduction

Cervical cancer is the third most frequent tumor-affecting women in Brazil, with more than 16,000 cases estimated for 2016 and 5,430 deaths registered in 2013 (inca.gov.br).

Cervical cytology is the most important preventive test for cervical cancer, responsible for a dramatic decrease in mortality.

There is discrepancy in published data, considering the superior efficiency of liquid based cytology (LBC) over the conventional cytology regarding the diagnosis of cervical epithelial abnormalities. While Siebers et al. [1] showed that there is no difference between the 2 methods, others describe better sensitivity and specificity of LBC [2–4].

Studies have shown that LBC leads to standardization in transferring collected cells and allows uniform fixation of cells, preserving their morphology, reducing blood, inflammatory cells, and mucus responsible for obscuring evaluation. Most importantly, LBC leads to a decrease in the diagnosis of atypical squamous cells of undetermined significance (ASC-US) [5–7].

An additional advantage is the preservation of nucleic acids allowing additional molecular testing of human papillomavirus (HPV) and other pathogenic agents in the same collected sample [8, 9].

There are 2 main commercially available methanol-based fixatives that have been used worldwide, PreservCyt[®] from Hologic[®] and SurePath[®] from BD Diagnostics[®], but they are too expensive to be implemented by the health system of underdeveloped or developing countries due to the differences in currency and import tax rates and costs.

The possibility to develop a low cost cytology fixative in countries with restricted budgets for the prevention of cervical cancer program may allow the spreading of the LBC technology.

Our aim was to test a new methanol-based fixative produced in the country (CellPreserv[®]) by Kolplast[®] and to compare it with the currently imported PreservCyt[®] produced by Hologic[®].

Methods

Our Institutional Board approved the study in April 2016 under the protocol 051/16.

A total of 725 women voluntarily participated in this study after signing an informed consent.

The inclusion criteria were healthy women, 18 years-old or older, who spontaneously visited the outpatient care for cervical cancer prevention in a private Sao Paulo's hospital from January to September 2016.

The cervical smears were collected by a trained health professional using a traditional device that was vigorously agitated in 2 mL PBS and equally divided (1 mL each) in vials containing 20 mL of PreservCyt[®] or CellPreserv[®], the new fixative in test.

Specimens were maintained at room temperature and sent to a central laboratory that processed all samples immediately. Before the preparation of slides for cytology evaluation, 1,000 µL was taken from each sample to search for HPV by polymerase chain reaction (PCR), using a protocol previously described [10]. The DNA was extracted with QIAamp DNA Blood mini kit (Qiagen). Amplification of the L1 conserved region of HPV was performed with primers MY09/11 (MY11-Fam-GCMCAGGGWCATAAAYAATGG; MY09-CGTCCMAARGGAACTGATC-Y = C + T/W = A + T/M = A + C/R = A + G) that detect 27 genotypes of high- (16, 18, 26, 31, 33, 35, 39, 45, 51, 52, 55, 56, 58, 59, 68, MM4, MM7, e MM9) and low-risk (6, 11, 40, 42, 53, 54, 57, 66, e MM8) HPV. The PCR products were

Table 1. Comparison of cytology results from 701 satisfactory cases from samples fixed in PreservCyt[®] and CellPreserv[®] solution

Results CellPreserv [®]	PreservCyt [®]						total
	negative	ASC-US	AGC	LSIL	HSIL	ASC-H	
Negative	653	3	0	1	0	0	657
ASC-US	5	18	0	2	0	0	25
AGC	0	0	5	0	0	0	5
LSIL	0	0	0	10	0	0	10
HSIL	0	0	0	0	3	0	3
ASC-H	0	1	0	0	0	0	1
Total	658	22	5	13	3	0	701

submitted to capillary electrophoresis in an ABI3730 Sanger sequencing equipment. Positivity was characterized by the presence of a 450 bp fragment using the Sanger method for identification of the virus subtype.

Since our goal was to validate the fixative, the cytology slides were prepared routinely using the ThinPrep 2000 system LBC slide processor (Hologic[®] Inc.), and the usual membrane and slides from ThinPrep[®]. The slides were stained by Papanicolaou and examined by 2 certified cytologists who were blinded and were reviewed by 1 experienced Cytopathologist using the 2014 Bethesda System for reporting cervical cytology [11].

We compared the results obtained by the 2 fixatives considering the adequacy category of satisfactory or unsatisfactory for evaluation, cytology result using Bethesda System, and HPV amplification by PCR.

Results

From 725 cases, 701 (96.7%) were satisfactory for cytological analysis by both methods. The mean age of patients was 39.7 years, ranging from 18 to 77 years.

The cytological diagnosis of specimens fixed with PreservCyt[®] and CellPreserv[®] is shown in Table 1.

The adequacy of samples was considered satisfactory, satisfactory but limited, and unsatisfactory in 436 (60.1%), 265 (36.6%) and 24 (3.3%), respectively, of samples fixed with PreservCyt[®] and 435 (60.0%), 267 (36.8%), 23 (3.2%) of samples fixed with CellPreserv[®].

Comparing the diagnosis of both fixatives, they were concordant in 99.3% of the cases. CellPreserv[®] did not detect 3 cases of ASC-US (3 cases diagnosed as negative for malignancy) and 3 cases of Low-grade Squamous Intraepithelial Lesion (LSIL; 2 cases diagnosed as ASC-US and 1 as negative for malignancy). Both fixatives detected all cases of high-grade squamous intraepithelial lesion (HSIL) [3].

Table 2. Comparison of cytology results in 36 HPV positive cases from 725 cases collected

	HPV positive cases					
	negative	ASC-US	AGC	LSIL	HSIL	ASC-H
PreservCyt®	23	5	1	5	2	0
CellPreserv®	25	5	1	3	2	0

The results regarding the HPV detection was 100% concordant between the 2 fixatives. From 701 specimens tested by HPV, 36 (5.1%) were positive, and all cases were satisfactory for cytological evaluation by the 2 fixatives. From HPV positive cases, the cytological results are presented in Table 2. From 36 HPV positive cases, cytology was negative in 23 (63.9%) of cases using PreservCyt® and in 25 (69.4%) cases collected in CellPreserv®. The HPV genotypes in negative cytology were HPV6 [7], HPV18 [6], HPV16 [3], and 1 of each HPV11, HPV33, HPV45, HPV52, HPV58, HPV61, and HPVMM7. Considering the 13 HPV positive cases with abnormalities in cytology using Thinprep® fixative, the viral genotype was HPV58 [3], HPV16 [3], HPV18 [2], HPV70 [1], HPV39 [1], and HPVMM7 [1]. In 2 cases, it was not possible to subtype the virus due to technical reasons. Considering viral subtype and cytology findings, HPV58 positive cases were diagnosed as LSIL [2] and ASC-US [1]. HPV16 was diagnosed as LSIL [2] and HSIL [1]. HPV18 was diagnosed as ASCUS and HSIL. HPV70 and MM7 were both diagnosed as ASC-US. The diagnosis was Atypical Glandular Cells for HPV39.

Discussion

Expenses for the public health system are the main concern in the establishment of cervical cancer screening programs. Cost-effectiveness studies address that the better performance of LBC reducing the number of false-negative test results, and the number of unsatisfactory specimens may be interesting, allowing larger intervals for screening, from 3 to 5 years [12]. Low-income countries have, by definition, lower productivity and underdeveloped industrialization, making it difficult to develop new methods that could be to be applied for cancer screening. Our goal with this study was the validation of a methanol-based new fixative for LBC produced in the country as a substitute of a traditional imported fixative for cervical cancer screening. The purpose is to turn the

method economically affordable for underdeveloped or in developing countries, since the commercially available products are expensive due to the currency value and costs related to the import process.

Considering the fixative PreservCyt® used in this validation study, the costs related to the fixative alone is 40% higher than that produced internally, turning the universal use of LBC by public prevention of cervical cancer program economically unviable.

Our results show that the performance of Cell-Preserv® is similar to that of the PreservCyt®, with concordance higher than 99%. There were only 4 false-negative cases, representing 0.57%. One case was diagnosed as LSIL and 3 as ASC-US by PreservCyt®. Five (0.7%) cases were false-positive cases, all diagnosed as ASC-US in PreservCyt® fixative.

Co-testing using the combination of Pap cytology plus HPV DNA testing is the preferred cervical cancer screening method for women who are 30–65 years old since it is cost effective and would be ideal for the large-scale healthcare public programs [13].

We have shown that HPV test was positive in a significant number of negative cytology cases using both fixatives, 23 with PreservCyt® and 25 with CellPreserv®. The similar number means that both are similar in the preservation of the viral genome and have no PCR interfering substances. This is one of the most important findings of our study, since literature shows that this method is more effective in preventing cervical cancer and some countries are planning to substitute cytology for DNA HPV testing for cervical cancer screening programs.

One of the advantages of the method mentioned in this study is that the comparison of the result was made between patients in one group and not in between patients of 2 different groups. On the other hand, the previous collection in PBS and posterior division between the 2 fixatives would compromise the adequacy of the sample mainly related to a smaller number of cells. However, it seems that it was not the case, since we had a small number of unsatisfactory cases related to cellularity. In addition, PBS could influence the appearance of cells; although it would be the same alteration in both split samples, it did not happen, being the cytological aspect preserved in all samples.

The majority of papers compare LBC with conventional Papanicolaou smear [2, 4, 14]. There are few studies comparing different methods of LBC. Published studies have shown better performance of SurePath® over Thinprep® in the detection of significant lesions [15, 16]. However, ours is the first study addressing the perfor-

mance of a new and cheaper fixative, thereby making this method affordable and universal in the treatment of LBC for low-income countries.

A motif of criticism would be the absence of biopsy results that could be considered the gold standard for both fixatives. However, literature shows that there is no gold standard, and indeed, cytology, colposcopy, and histology are all subjects to variable performance [17].

In summary, our study validates a new and cheaper fixative for LBC and HPV detection to be used by the public health system for cervical cancer screening.

Disclosure Statement

The authors have no conflicts of interest to declare.

References

- Siebers AG, Klinkhamer PJ, Grefte JM, Masingier LF, Vedder JE, Beijers-Broos A, et al: Comparison of liquid-based cytology with conventional cytology for detection of cervical cancer precursors: a randomized controlled trial. *JAMA* 2009;302:1757–1764.
- Fremont-Smith M, Marino J, Griffin B, Spencer L, Bolick D: Comparison of the SurePath liquid-based Papanicolaou smear with the conventional Papanicolaou smear in a multi-site direct-to-vial study. *Cancer* 2004;102:269–279.
- Beerman H, van Dorst EB, Kuenen-Boumaester V, Hogendoorn PC: Superior performance of liquid-based versus conventional cytology in a population-based cervical cancer screening program. *Gynecol Oncol* 2009;112:572–576.
- Longatto-Filho A, Levi JE, Martins TR, Cohen D, Cury L, Villa LL, et al: Critical analyses of the introduction of liquid-based cytology in a public health service of the state of Sao Paulo, Brazil. *Acta Cytol* 2015;59:273–277.
- Colgan TJ, McLachlin CM, Cotterchio M, Howlett R, Seidenfeld AM, Mai VM: Results of the implementation of liquid-based cytology-SurePath in the Ontario screening program. *Cancer* 2004;102:362–367.
- Payne N, Chilcott J, McGoogan E: Liquid-based cytology in cervical screening: a rapid and systematic review. *Health Technol Assess* 2000;4:1–73.
- Weintraub J, Morabia A: Efficacy of a liquid-based thin layer method for cervical cancer screening in a population with a low incidence of cervical cancer. *Diagn Cytopathol* 2000;22:52–59.
- Cox JT: History of the use of HPV testing in abnormal cervical screening results. *J Clin Virol* 2009;45(suppl 1):S3–S12.
- Albrow R, Kitchener H, Gupta N, Desai M: Cervical screening in England: the past, present, and future. *Cancer Cytopathol* 2012;120:87–96.
- Qu W, Jiang G, Cruz Y, Chang CJ, Ho GY, Klein RS, et al: PCR detection of human papillomavirus: comparison between MY09/MY11 and GP5+/GP6+ primer systems. *J Clin Microbiol* 1997;35:1304–1310.
- Nayar R, Wilbur DC: The Pap test and Bethesda 2014. *Cancer Cytopathol* 2015;123:271–281.
- Karnon J, Peters J, Platt J, Chilcott J, McGoogan E, Brewer N: Liquid-based cytology in cervical screening: an updated rapid and systematic review and economic analysis. *Health Technol Assess* 2004;8:iii, 1–78.
- Beal CM, Salmeron J, Flores YN, Torres L, Granados-Garcia V, Dugan E, et al: Cost analysis of different cervical cancer screening strategies in Mexico. *Salud Publica Mex* 2014;56:429–501.
- Simion N, Caruntu ID, Avadanei ER, Balan R, Amalinet C: Conventional cytology versus liquid based cytology in cervical pathology: correspondences and inconsistencies in diagnosis, advantages and limits. *Rom J Morphol Embryol* 2014;55:1331–1337.
- Rozemeijer K, Penning C, Siebers AG, Naber SK, Matthijse SM, van Ballegooijen M, et al: Comparing SurePath, ThinPrep, and conventional cytology as primary test method: SurePath is associated with increased CIN II+ detection rates. *Cancer Causes Control* 2016;27:15–25.
- Rozemeijer K, Naber SK, Penning C, Overbeek LL, Looman CW, de Kok IM, et al: Cervical cancer incidence after normal cytological sample in routine screening using SurePath, ThinPrep, and conventional cytology: population based study. *BMJ* 2017;356:j504.
- Stoler MH, Schiffman M: Atypical Squamous Cells of Undetermined Significance–Low-grade Squamous Intraepithelial Lesion Triage Study (ALTS) Group: Interobserver reproducibility of cervical cytologic and histologic interpretations: realistic estimates from the ASCUS-LSIL Triage Study. *JAMA* 2001;285:1500–1505.

#00013

INCIDENCE OF CERVICAL LESIONS ASSOCIATED WITH HUMAN PAPILLOMAVIRUS INFECTION IN WOMEN LIVING IN TRIBUTARY COMMUNITIES OF AMAZONAS RIVER - BRAZIL

M. Zonta¹, K. Bonilha¹, M. Shuio¹, B. Otta¹, C. Kiffer²,
¹Santo Amaro University (Brazil), ²Federal University of São Paulo (Brazil)

Background / Objectives

Introduction: Cervical cancer remains a world public health problem. The relationship between this neoplasia and human papillomavirus infection is well established. In Brazil, the National Cancer Institute (INCA) predicts that there will be 16,300 new cases of the disease in 2018. There are no reports of cases about this neoplasm in the riverine populations of the Amazon River and its tributaries, leaving this population deprived of medical assistance and programs of cancer prevention.

Objective: The present work aims, by using a liquid-based cervical cytology followed by a Human Papillomavirus (HPV) genotyping, to identify the incidence of HPV infection, a precursor lesion of cervical cancer, in cervical samples from women living in the riverside of Negro and Madeira River.

Methods

Method: 123 cervical samples were collected in a liquid medium (Cellpreserv) and automatically processed on KLP 2000 equipment (Kolplast®). Two cytologists analyzed the cellular material subjected to conventional Papanicolaou staining and classified the results by Bethesda System (2011). The HPV genotyping was performed using the MicroArray (Euroimmun®) method in duplicate. Data were analyzed statistically by the Mann-Fisher exact test and the chi-square test. The study was duly approved by the Ethics Committee of the Santo Amaro University - SP (Brazil Platform - CAAE: 61414216.4.0000.0081).

Results

Results: Of the 123 cellular samples, 65 samples were from Negro River riverside population and among of them 12.32% showed squamous intraepithelial lesions with neoplastic potential such as ASCUS (1.54%), LSIL (6.15%) and HSIL (4.62%). The highest incidence of HPV types were 16, 45, and 61 (21.43%). Others 58 cellular samples were from Madeira's riverside population and 6.7% showed cervical intraepithelial lesions with neoplastic potential, of them ASCUS (1.72%), LSIL (1.72%) and HSIL (3.45%) The incidence of HPV infection, in both regions, was 31 (25.20% samples analyzed by molecular test, being HPV 16 (4.87%) and HPV 45 and 53 (3.25%) the most prevalent types. The highest incidence of HPV infection was in women aged less than 25 years (43.75%) and over 50 years (27.27%), compared to women aged between 26 and 49 years (X²= 9.64 p = 0.0081). Viral infection was more frequently found among single women than

Conclusion

Conclusion: Our results showed a high risk of developing cervical neoplasia in young and single women due to the great incidence of high-grade squamous intraepithelial lesions (HSIL) associated with HPV types of high oncogenic risk found in women living in the riverside communities near the Madeira and Negro River, tributaries of the Amazon River.

References

Ferlay J, Bray F, Pisani P, Parkin DM. Globocan 2002 Cancer Incidence, Mortality and Prevalence Worldwide. IARC CancerBase N°5, version 2.0, IARC Press. Lyon; 2004.
Duarte- Franco E, Franco EL. Cancer of the the uterine cervix. BMC Women's Health 2004; 4: S13.

INCA. Sistema de câncer de base populacional [on-line]. 2007 [citado em 2007 24 de Julho]. Disponível em: URL: <http://www.inca.gov.br/cgi/sisbasepop.asp>
Ministério da Saúde. Sistema de Informações sobre Mortalidade – SIM [Online]. 2007 [citado em 24 de Julho de 2007]. Disponível em: URL: <http://tabnet.datasus.gov.br/cgi/deftohtm.exe?sim/cnv/obtudef.def>

Franco EL, Villa LL, Sobrinho JP, Prado JM, Rousseau MC, Desy M, et al. Epidemiology of acquisition and clearance of cervical human papillomavirus infection in women from a high-risk area for cervical cancer. J Infect Dis 1999; 180: 1415-23
Kjaer SK, van den Brule AJ, Paull G, Svare EI, Sherman ME, Thomsen BL, et al. Type specific persistence of high risk human papillomavirus (HPV) as indicator of high grade cervical squamous intraepithelial lesions in Young woman: population based prospective follow up study. BMJ 2002; 325-572.

Rousseau MC, Abrahamowicz M, Villa LL, Costa MC, Rohan TE, Franco EL. Predictors of cervical coinfection with multiple human papillomavirus types. Cancer Epidemiol Biomarkers Prev 2003; 12: 1029-37.

Trottier H, Mahmud S, Costa MC, Sobrinho JP, Duarte Franco E, Rohan T, et al. Human papillomavirus infections with multiple types and risk of cervical neoplasia. Cancer Epidemiol Biomarkers Prev 2006; 15: 1274-80.
Winer RL, Hughes JP, Feng Q, et al. Early natural history of incident, type-specific human papillomavirus infections in newly sexually active young women. Cancer Epidemiol Biomarkers Prev 2011;20(04):699–707

Moore MA, Tajima K. Cervical cancer in the asian pacific-epidemiology, screening and treatment. Asian Pac J Cancer Prev 2004; 5(04):349–361

Vieira RC, Monteiro JdoS, Manso EP, et al. Prevalence of typespecific HPV among female university students from northern Brazil. Infect Agent Cancer 2015; 10:21

BRAZIL, National Institute of Cancer José Alencar Gomes da Silva. Estimativa 2012: Incidência de Câncer no Brasil, Instituto Nacional do Câncer, Rio de Janeiro, Brazil, 2011.

G. N. L. Camara, D. M. Cerqueira, A. P. G. Oliveira, E. O. Silva, L. G. S. Carvalho, and C. R. F. Martins, "Prevalence of human papillomavirus types in women with pre-neoplastic and neoplastic cervical lesions in the federal district of Brazil," Memórias do Instituto Oswaldo Cruz, vol. 98, no. 7, pp. 879–883, 2003.